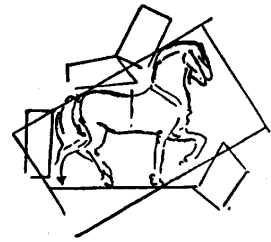


Dr. med. vet. D. J. Riemersma

Dipl.ECVS, FTA Pferde, Specialist Chirurgie van het Paard (NL)
Traberpark "Den Heyberg" B299
Im Auwelt 45
47624 Kevelaer - Twisteden

Tel. 02832 952 299 Fax : 02832 952 799 Handy : 0172 257 257 5



Dr. med. vet. D. J. Riemersma - Im Auwelt 45/299 - 47624 Kevelaer

Newport Breeding B.V.
dHr. Peter Ter Borgh
Zuiderweg 21
NL-1461 GB Zuidoostbeemster

Pferd: Outlaw Newport, Traber, 75200211S213185, Hengst, Braun, geb: 20.03.2021

Osteochondrosis dissecans (X-ray's)

Tarsal joint (hock)	LH: OCD was removed	RH: -
Stifle:	LH: -	RH: -
Fetlock joint:	LF: -	RF: -
	RF: -	RH: -

All other above mentioned joints are without any signs of ocd. X-ray's were taken by another vet.

